

Asphericity, Spherical Aberrations and Ablation Innovations

David Santiago, O.D.
LaserSight Technologies, Inc., Winter Park, Florida, U.S.A.



David Santiago O.D.

美国波多黎哥大学眼视光学学院眼视光学博士。

国际OK镜协会会员，现任美国雷赛技术股份有限公司国际市场营销部经理、临床事务部经理。

David Santiago在OK镜、硬性透气角膜接触镜、圆锥形角膜领域有22年丰富临床实践经验。

Multi-dimensions, Multi-axes, Eye modeling

Eye is

- Dynamic
- Multiple axes
- Asymmetrical
- Multiple parameters
- Changing

Cornea

- More stable
- More symmetrical
- Less dynamic

What is important?

- Shape
- Orientation (axis)


Multi-dimensional data acquisitions

- Refractive error measurement
- Correction Prescription (Gold standard)
- Corneal topography
- Pupilometry
- Wave front measurement
- Pachymetry
- Axes and Orientation
- Multi-dimensional Data alignment

Patient Positions and Alignment

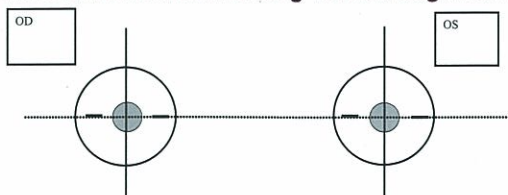
- The eye changes with
 - Sitting position
 - Supine position
- Torsion changes has marginal effect
 - Sphere, no effect
 - Cylinder, vector analysis, marginal residual astigmatism

Torsion Changes

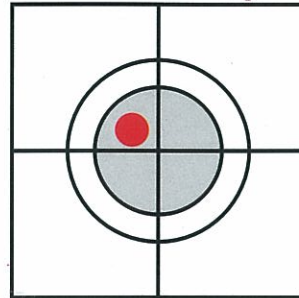


- Slight rotational error induces marginal residual astigmatism
- Torsion/rotational error does not change postop corneal vertex normal

Bilateral Horizontal Marking Torsion alignment



Ablation Center Changes



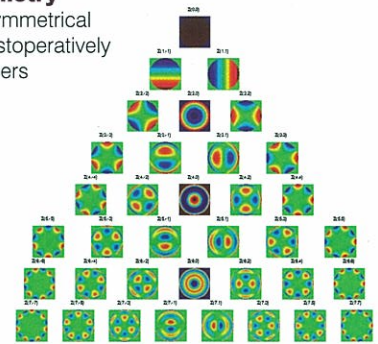
- Induce astigmatism
- Change of post-operative corneal vertex normal
- Cause rotation of eye post-operatively when fixating to a target
- Induce coma
- Induced astigmatism and coma most dramatic for oblate shape post-operatively

Laser Corneal Refractive Vision Correction Criteria

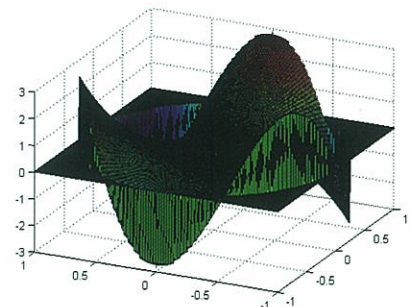
- Multi-parameter Optimization
- Because cornea is nice and symmetrical
- Create a normal post-operative cornea
- That maintains the shape and orientation

Get rid of asymmetry

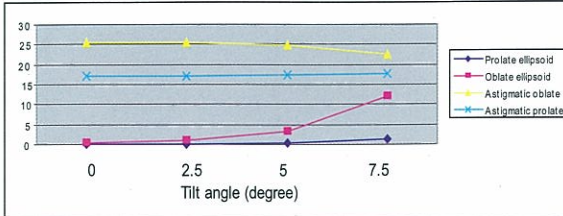
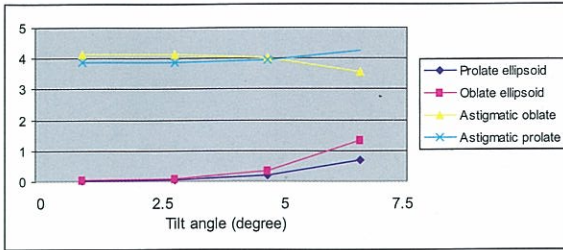
- No significant asymmetrical Zernike terms postoperatively
- Optical zone matters



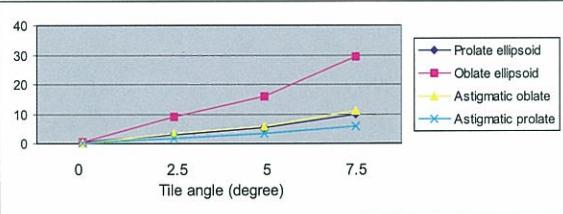
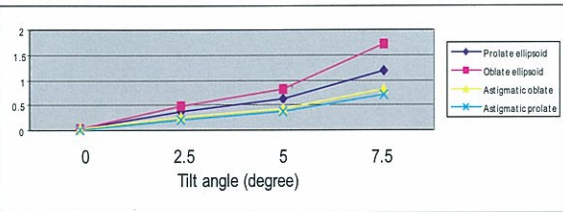
Coma



Induced Astigmatism

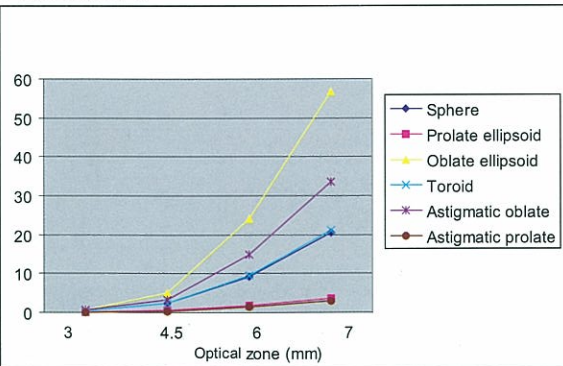


Induced Coma



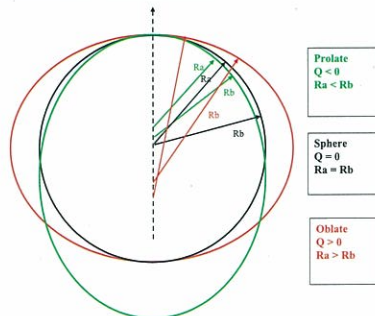
Minimize total spherical aberration

- Negative Q
- Customized Q

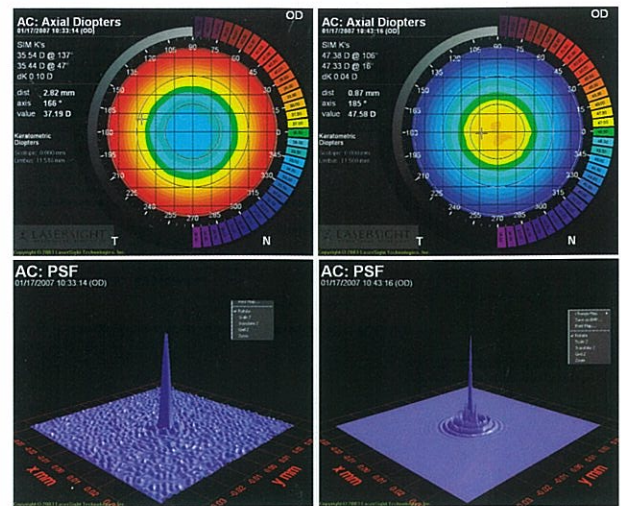


Shape Matters

Prolate or Oblate

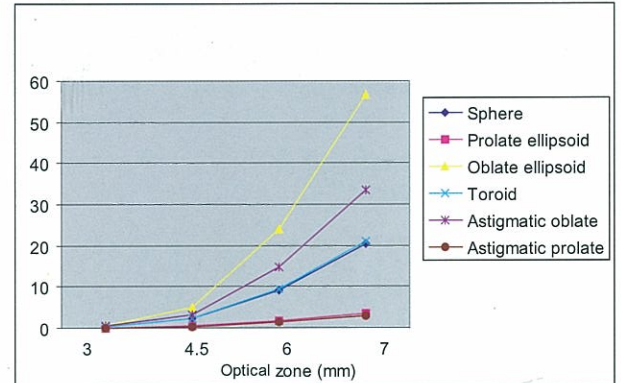


Shape Matters - Spherical, Oblate and Prolate



Spherical aberration

Changes with Q and Optical Zone



Prolate vs. Oblate

- Lower spherical aberration
- Lower induced astigmatism
- Lower induced coma
- Prolate Shape is Superior Optically!

Complex Cornea Treatment

- Complex cornea
- Marginalized assumptions
- Not a good shape
- Improper axis
- Wrong corneal vertex normal

Rotation and Translation?

- Cause of Decentration
 - Translation (Shift)-ablation error
 - Rotation -fixation error
 - Shift induces rotation
- Measurement of Decentration
 - Topography
 - Induced fixation error (Rotation)
- Solution to Fix the Problem
 - Translation (shift) of corneal vertex
 - Opposite shift induces opposite rotation
 - Cancel induced rotation (fixation) error

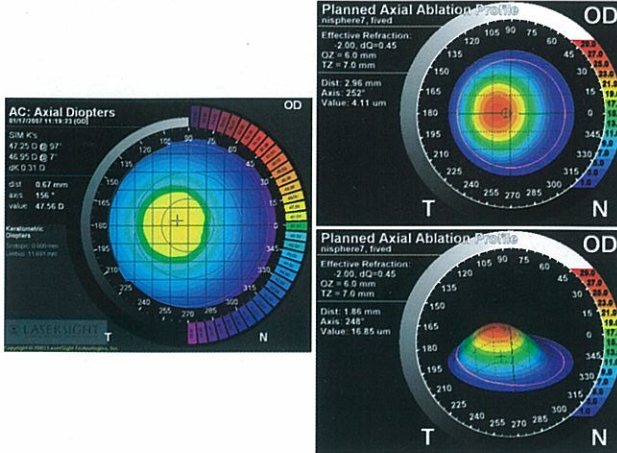
Solutions for Complex Corneas

- Force the change of post-op corneal vertex
- Translation (shift) of post-op corneal vertex

- Opposite shift induces opposite rotation
- Cancel induced rotation (fixation) error
- Restore the "original" / "optimized" corneal vertex normal
- Restore Line of sight
- Restore vision

Asymmetrical Cornea

5 degree tilt corrected by 44 microns corneal vertex shift less than 0.28 degree tilt error



Alignment and registration

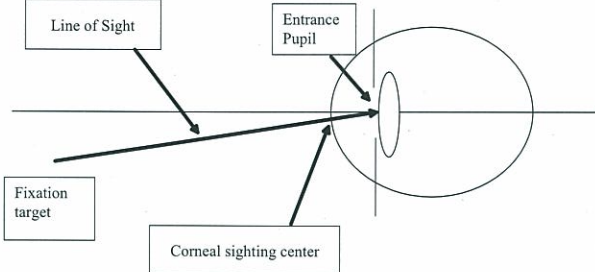
- Pupil center changes
- Pupil size changes
- Alignment and fixation: line of sight
- Initial registration (locking)

Registration and Tracking

- Tracking of pupil center
- Alignment during Measurement
- Alignment prior to surgery
- Alignment during surgery

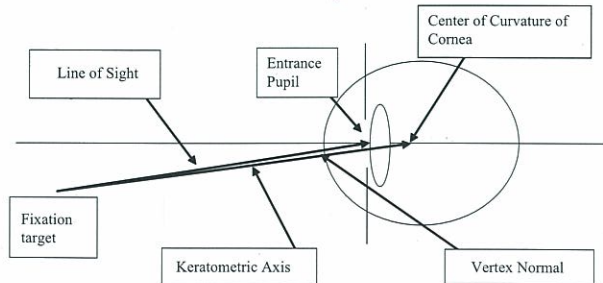
Axis: Line of sight

Corneal sighting center or visual center of the cornea



Keratometric Axis

intersects the cornea normally

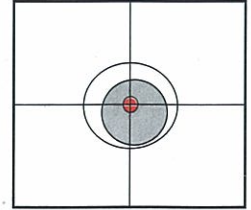


- At the vertex normal, the light ray from the fixation point hits the cornea along the surface normal in 3D, therefore perpendicular to the surface.

Data Centers

Alignment during Measurement

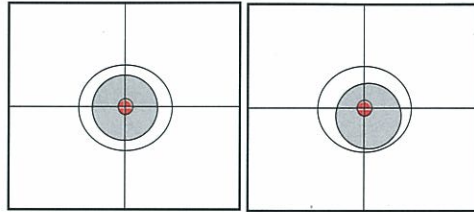
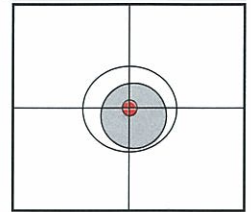
- Patient fixation
- Enter on pupil
- Center on Vertex normal



Data Centers

Alignment During Treatment

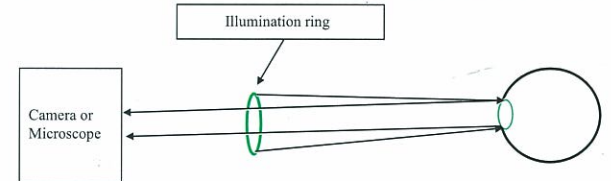
- Patient fixation
- Pupil center
- Corneal Vertex



Where is the gap?

- Patient dependent
- Operator dependent
- Instrument error
- Measurement error
- Alignment error
- Tracking error
- All errors compound!

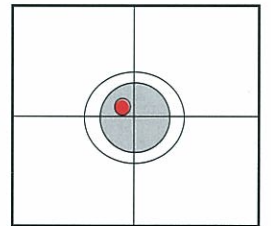
Illumination ring - live and in-situ CT center detection



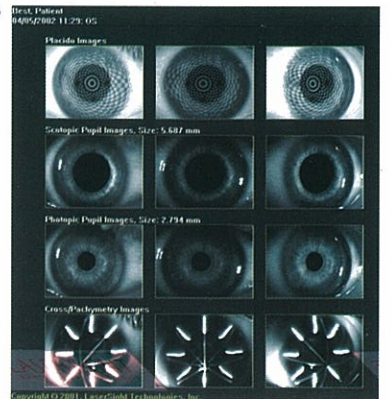
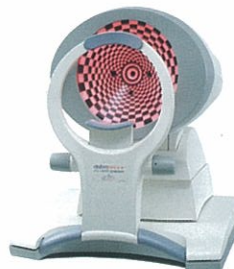LaserSight:

In-situ Pupil Registration

- Corneal vertex center as treatment center
- In-situ pupil offset detection
- Computer image acquisition & processing
- Alignment, registration and tracking combined
- Combines Intelligence of Surgeon and Advancement of technologies
- Error minimized



Knowledge Empowers LaserSight AstraMax




Knowledgegap Matters: LaserSightAstraPro P, Q and Z

- P - Prolate, Better Optical Property
- Q-Optimize Post-op Prolateness Customized Optical Property
- Z-Restore/Optimize Post-op corneal ve-rtex normal/line of sightTissue Saving

LaserScan Performs: A Precision Carving Tool

- Scanning, gentle touch technology
- Ideal for LASIK/PRK
- LASIK/PRK
- Precision scanning in X-Y
- Precision in ablation per pulse(Y)
- Sync eye tracker
- In situ registration!
- Performs what AstraPro planned



Clinical results Highlights

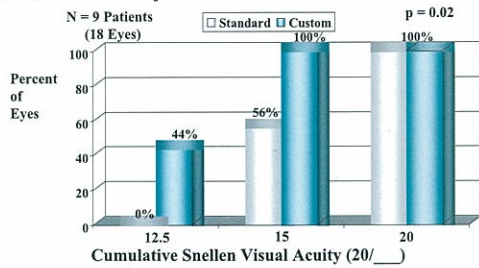
- Primary eyes
- Contrast sensitivity
- Subjective measurement
- Complex cases
- Multiple sites
- Multiple surgeons
- Different times

Custom ablation for Primary Eyes

- Standard ablation vs. Custom Ablation
- Double blind study
- Objective measurement comparison
- Subjective questionnaire
- Subjection contrast sensitivity study

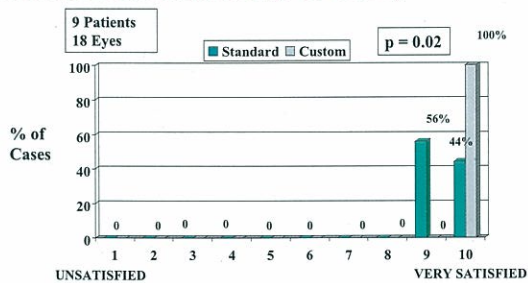
Courtesy of A. Stojanovic, M.D., Norway

3-Month Postop UCVA



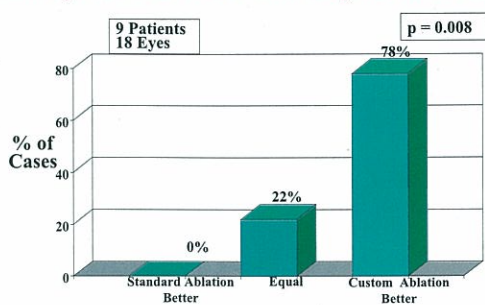
Courtesy of A. Stojanovic, M.D., Norway

PATIENT SATISFACTION (1-10 Scale)



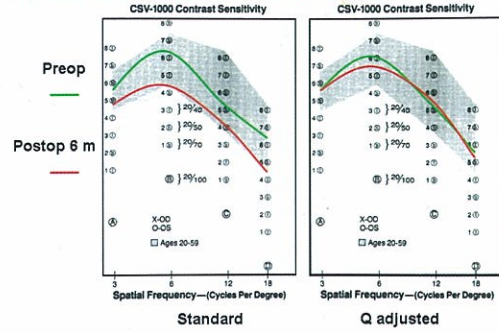
Courtesy of A. Stojanovic, M.D., Norway

Which Eye Do You Prefer With Regard To Vision Quality?



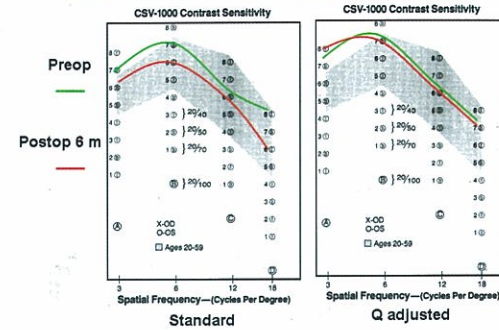
Courtesy of Shihao Chen, M. D. and Qinmei Wang, M.D., Wenzhou, China

Contrast Sensitivity Test Scotopic



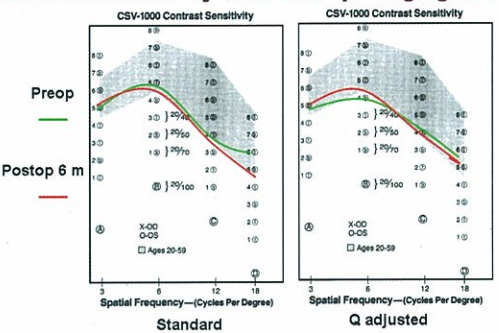
Courtesy of Shihao Chen, M. D. and Qinmei Wang, M.D., Wenzhou, China

Contrast Sensitivity Test, Mesopic low glare



Courtesy of Shihao Chen, M. D. and Qinmei Wang, M.D., Wenzhou, China

Contrast Sensitivity Test Mesopic high glare



Conclusions on Primary Treatment

- Custom Treatment is superior to Standard Treatment
- Subjectively
- Objectively

Clinical Cases For Complex Corneas

Courtesy of Liangcheng Wu, M.D., Shanghai Peace Eye Hospital, Shanghai, China

